

**SUCCESSFUL AYURVEDIC MANAGEMENT OF BILATERAL BREAST ABSCESS
WITH MENTAL DEPRESSION - A CASE REPORT****Dr. Sarita Pradip Gaikwad***

M.D., Ph.D.(Kayachikitsa), Director, Punarnava Trimarma Chikitsalay, Ganeshnagar Road, Nanded-431 602 (India).
Ex HoD, Ayurved Research Department, Sassoon General Hospital, Pune (India).
Vol. Retd. Assistant Director, AYUSH, Pune Region, Pune.

***Corresponding Author: Dr. Sarita Pradip Gaikwad**

M.D. (Manas Rog), PhD (Kayachikitsa), Director, Punarnava Trimarma Chikitsalay and Research Centre, Nanded-431 602.

Email Id: sarita.pgaikwad@gmail.com Mobile No: +91 9822025105

Article Received on 11/10/2022

Article Revised on 01/11/2022

Article Accepted on 21/11/2022

ABSTRACT

Bilateral breast abscesses are commonly encountered in clinical practice. Most commonly it is observed in lactating women. Management of bilateral breast abscesses is challengeable as sometimes there is recurrence noted. **Case report:-** A 22 year old female delivered a full term normal female baby in Sassoon General Hospital, Pune on 15.10.2015. As the female patient lost her mother on the same day of the delivery, she did not breastfed her baby for next 3 days. That caused her bilateral severe mastitis followed by breast abscess. She was admitted in a tertiary care hospital on 29.10.2015. Debridement surgery was done on Breast abscess on 3.11.2015 which was repeated again on 7.11.2015. But the wound failed to heal. Finally the case was transferred to Ayurved department of Sassoon General Hospital, Pune on 17.11.2015. She was administered Ayurvedic line of treatment that consisted of *Vran chikitsa*/Local treatment, *Abhyantar chikitsa*/Oral treatment and *Panchakarm chikitsa*. The case was completely healed within 100 days, without using antibiotics, modern drugs and plastic surgery. **Conclusion:** Ayurved has strength and ability to treat complicated cases like this case having bilateral breast abscess. There was no recurrence even after 7 years.

KEYWORDS: Bilateral breast abscess, Mastitis, *Ubhay stan Bhagi vidradi- Dushta vran*.**INTRODUCTION**

Breast abscess is commonly observed in lactating mothers. Its incidence is 0.4% to 11%.^[1] There may be recurrence within 24 weeks of follow up.^[2] Its management is a skillful job. It was reported that breast abscesses can be treated by repeated needle aspirations and suction drainage. Where an abscess has been formed, aspiration of the pus, preferably under ultrasound control, has now supplanted open surgery as the first line of treatment.^[3]

CASE REPORT

This 22 year old female delivered a female child in Sassoon General hospital on 15.10.2015. She breastfed the baby on the day of delivery. The mother of the patient died on the same day. On receiving this news, she stopped feeding the baby for next 3 days. On the fourth day there was breast engorgement on left side with black discoloration. On the next day Rt. breast also showed breast engorgement with black discoloration. There were few vesicles like lesions appeared on both of the breasts. A sticky discharge started flowing from the lesions. Patient reported to Surgery department of Sassoon General hospital, Pune on 29.10.2015 and was admitted in Surgery ward immediately. Findings of surgeon were as follows:

A 22 year old female G₂P₁L₁A₁
C/o -B/L Breast engorgement ++
-B/L Tenderness ++
Not breastfed baby for 3 days
No H/o Trauma, No H/o Chronic cough. No H/o Medical illness in the past.
O/E: Afebrile, Pulse-80/min, B.P.-110/80 mm Hg
RS/CVS-NAD
P/A: Soft. No tenderness, guarding and rigidity.
Local examination:-Blackish discoloration of whole left breast ++. Local temperature raised bilaterally; Rt. Breast Cellulitis+
Δ B/L breast engorgement with Rt. Breast Cellulitis.
Local USG B/L Breast was done on 29.10.2015
-Extensive subcutaneous oedema is noted.
-Underlying breast tissue appears heterogeneously hypochoic.
-No obvious focal collection noted.
Impression: Above features S/o Infective etiology affecting B/L mammary glands.
Clinical correlation suggested.
Clinical notes on 30.10.2015:
Lt breast-tense, Fluctuation + Aspiration + for pus.
Skin showing blackish discoloration + over both breasts.

Apirated pus was sent for culture & sensitivity. On 3.11.2015 B/L Breast abscess Debridement was done under General anaesthesia. Debrided wound was washed by using Hydrogen peroxide and Betadine. Monocef and Vancomycin antibiotics were administered. She was administered Tab Cabergoline 0.5 mg- a dopamine agonist, for treating hyperprolactinemia with the aim of stopping breast milk secretion. Baby was advised top feeding for 6 months.

Patient was again operated for debridement surgery under sedation on 7.11.2015.

Wound wash was done using Hydrogen peroxide and Betadine. As per advice of Plastic surgeon dressing was done using Aloe vera gel. The wound failed to heal and finally it was decided to transfer the case to Ayurved department on 17-11-2015, where the case was admitted till she was discharged on 25.2.2015 after complete healing of both the wounds. On admission to Ayurvedic ward, patient was thoroughly examined %

G₂, P₁, L₁, A₁; delivered on 15.10.2015

Family history (*Kulaj-vritta*)- Nothing particular (*Avishesh*)

Addicted to tobacco chewing for last 4 years.

General exam:- Afebrile

Pulse-98/min B.P.-100/60 mm Hg

Tongue/*Jivha*- Coated/ *Nirama*

Appetite-Normal, Thirsty, Passing of urine and bowel movements - normal

Systemic exam-Nothing abnormal detected.

Local examination: *Ubhay stan Bhagi vidradi- Dushta vran*, (Bilateral non healing debrided wound) with Bluish discharge. *Vaivarna* on both breasts +

Investigations: Hb-6.6 gm/dL, Total Proteins-5 gm/dL, Albumin-2.1 gm/dL, Globulin-2.9 gm/dl; SGOT-9 units/L, SGPT-12 units/L.; Total Bilirubin-0.5 mg/dL. Serum Creatinine- 0.8 mg/dL; Blood urea- 31 mg/dL. Na⁺ -139 mEq/L, K⁺-4.3 mEq/L

Chikitsa/ Treatment: Treatment was based on sound principles of Ayurved, namely *Nidan-Parivarjan, Satvavjay chikitsa, Abhyantar chikitsa, Panchkarma chikitsa and Vran chikitsa.*

Nidan-Parivarjan:- Patient was addicted to tobacco chewing. She was motivated to leave habit of tobacco chewing. Patient was asked to consume *Laghu-Supachya aahar*.

Satvavjay chikitsa:- Patient had recently lost her mother and in that grief she did not breastfed her baby. That was the trigger point of her present illness. She was counseled adequately to enable her to accept the reality of death for everyone. It was made her realize that due to her irresponsible act, she was suffered and also caused suffering for the poor baby. This treatment enabled to reduce her mental depression.

Abhyantar chikitsa

1. Tab Gandhak rasayan 2BD for 15 days followed by a gap of 7 days to restart the treatment for 15 days;

this was the schedule of treatment for 3 months period.

2. Tab Sookshma Triphala (Rasa shala, Pune) 2BD for 3 months period.
3. Amrutadi guggul:- 2BD for 3 months period
4. Gokshuradi guggul: 2BD for 3 months period
5. Madhumalini vasant:- 1BD for 3 months period
6. Mixture of Musta (*Cyperus rotundus*) + Haridra (*Curcuma longa*) + Guduchi (*Tinospora cordifolia*) + Ashwagandha (*Withania somnifera*) - 1TSF BD for 3 months.
7. Soonthi (*Zingiber officinalis*) + Haridra (*Curcuma longa*) + Shatavari (*Asparagus recemosus*) siddha milk 1 cup BD

Patient was advised to consume 2 boiled eggs daily along with 15 gm non salted baked Bengal gram in the breakfast, which fulfilled the raised protein requirement of the patient.

Local treatment/ *Sthanik chikitsa*:- The debrided wound was washed daily with the decoction made of boiling skin of Vata (*Ficus bengalensis*), Udumbar (*Ficus racemosa*), Pipal (*Ficus religiosa*); it was dried and dressed with *Vran Shodhan tail*. When granulation tissue started appearing, the wound was dressed with *Vran-ropan tail*. (Fig. No.3). The size of the wound was quite big, that caused complete healing in less than 100 days (Fig. No.4). The wound was completely healed without using any modern antibiotic or healing by plastic surgery.

DISCUSSION

The reason of formation of bilateral breast abscess was, failure to breastfeed the baby for 3 days, which triggered the disease process. As the milk was not extracted out, it remained in the breast which was a favorable environment for growth of the bacteria *Staphylococcus aureus*.^[4] Patient had developed Severe mastitis but approached quite late and there was delay in starting proper treatment. Therefore Mastitis was converted in to breast abscess. Dener C et al reported that delayed treatment of mastitis can lead to abscess formation, and it can be prevented by early antibiotic therapy.^[2] It was pointed out that after debridement of both the breasts, wound was washed with Hydrogen peroxide and Betadine. It is highlighted here that **Hydrogen peroxide and Povidone iodine (Betadine) have been proved to be cytotoxic that inhibit the proliferation of fibroblasts.**^[5] That might be a crucial factor in non healing of the wound.

As per Ayurved, wound/*Vran* at the breast site is difficult to cure. Vagbhat had stated following sites of wound which are difficult to treat namely: eyes, teeth, *apang*/*Pterion*, breast, ear, *Parshwa*/*Gluteal* region, *Kaksha*/*armpit*, abdomen, around *Nabhi*/*umbilicus* as mentioned in the verse below.^[6]

Krichchha sadhyo Akshi Dashan Nasika Apang Nabhishu I Sevani Jathar Shrotra Parshwa Kaksha Staneshu Cha II Sarth Vagbhat Uttar sthan 25/15.

Long before that Sushrutacharya mentioned it in Su. Sutra sthan 23/6.

After 15 days of treatment patient was administered Saddho vaman as stated by Vagbhat.^[7]

Athatra Shofavasthayam Yathasannam Vishodhanam II

Yojoyam Shofa hi Shuddhanam Vranashchashu Prashamyati I

Sarth Vagbhat Uttar sthan 25/23.

When there is inflammation, it is treated by Vaman/Rechak/Nasya and after removing the dosha, inflammation and Vran/wound gets easily cured.

On appearance of granulation tissue Patient was administered 7 days course of Matra basti by Narayan tail. Shatavari is called as Narayani. Matra basti administered of Narayan tail nourished the *Mauns dhatu* of Uterus and Sthanya/ breasts.

This case having infective origin, as per modern science, it is normally treated by giving antibiotics based on Culture & Sensitivity. **The culture & sensitivity is the gift of Modern medicine, but treatment based only on Sam-Niram awastha, without knowing bacteria or viruses is the gift of Ayurved!** Ayurved does not require getting Culture & Sensitivity done. Ayurved creates an environment that does not promote the growth of microorganisms. Gandhak rasayan and Sookshma Triphala are Ayurvedic antibiotics that prevent growth of microorganisms. The most conspicuous advantage of them is that that there is no resistance developed to these drugs in thousands of years used in clinical practice.

Gandhak rasayan contains Gandhak i.e. Sulphur, which has hepatotoxic properties, hence to reduce toxic effects, its use was made intermittently. It is further clarified here that while preparing Gandhak rasayan in ghrita, most of the toxic effects are removed but for taking extra precaution, we used it intermittently.

Madhumalini vasant was used as it acts on *Mauns Dhatu*. Amrutadi guggul contains Guduchi (*Tenospora cordifolia*) which is a *Rasayan* drug that has properties of *Dhatwagni pradipak*, *Vatanashak* and *Jwarghna*-reduces inflammation.^[8]

Patient was administered a combination of Musta (*Cyperus rotundus*) + Haridra (*Curcuma longa*) + Guduchi (*Tinospora cordifolia*) + Ashwagandha (*Withania somnifera*). Let us see the action of each one. Musta is Tikta & Katu rasatmak, reduces unwanted secretions, it has Vatanashak properties and itself is Jathragni deepak as mentioned by Rajvallabha in the verse below:

Mustakam Tiktakatukam Vatagnam Grahideepanam I Rajvallabha:

Haridra Kapha-Pittaghi Kandu Twagdoshanashini I

Pandu-Shothapachi Chaiv Mehakushtavranapaha II Rajvallabha:

Haridra is Kapha-pittanashak, very useful in itchy skin disorders, Pandurog (Anemia), Shoth (oedema), Apachi, Prameha (Diabetes), Kushta rog and Vrananashak-healing of infected wounds. It has been having proved Antibacterial properties, specially on gram positive bacteria like *Staphylococcus aureus*.^[9]

Triphala is combination of Haritaki (*Terminalia chebula*), Amla (*Phyllanthus emblica*), Behada (*Terminalia bellirica*). It has Vran-ropak, Vran strav awarodhak, Netra rog nashak, Nashak of Medorog, Meha, Kapha and Dushta-rakta properties.^[10]

Ashwagandha (*Withania somnifera*) gives strength to *dhatu* and causes *Shaman* of *Vata vikar*.^[11]

Sunthi (*Zingiber officinalis*) carries out *Deepan-Pachan* used as *Aam-Pachak* and *Vatanashak*, Shatavari (*Asparagus recemosus*) is *Pittashamak* and nourishes breast; therefore its use was made in Siddha milk.

The author had successfully used Quath made from the bark of Vat vikar (*Ficus indicus/ bengalensis*), Udumbar (*Ficus racemosa*), Ashwath (*Ficus religiosa*) for treating non healing/ trophic ulcers in Leprosy patients. Same was used to wash the debrided wound of both mammary glands.^[12]

Healing of wound requires high protein diet as body needs protein to help build and repair muscle, skin, and other body tissues. Protein helps to fight infection, balance body fluids, and carry oxygen throughout the body.^[13] Patient was economically poor but she was arranged a special diet containing 2 boiled eggs and 15 gm of baked Bengal gram daily.

Thus using the basic principles in Ayurved as mentioned earlier, this case was successfully completely healed. The most conspicuous fact is that there was no recurrence in last 7 years.

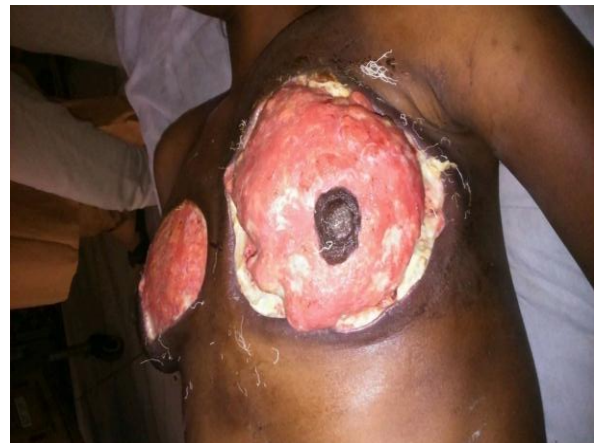

Figure 1: Before ayurvedic treatment.

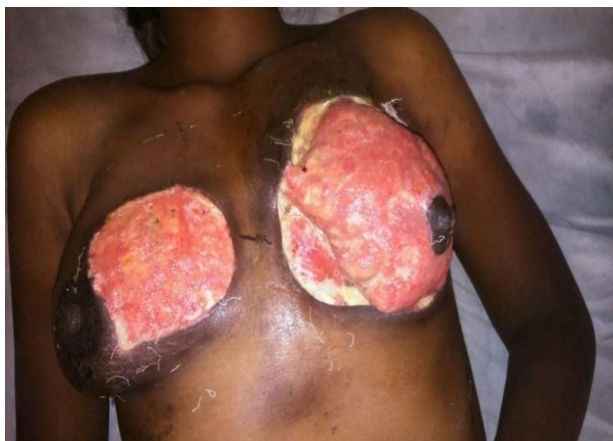

Fig. no. 2: After 15 days of ayurvedic treatment.

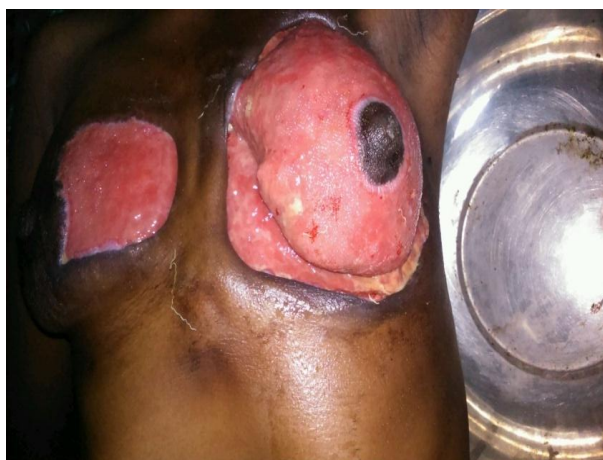


Fig. no. 3: On completion of 1 month of treatment.

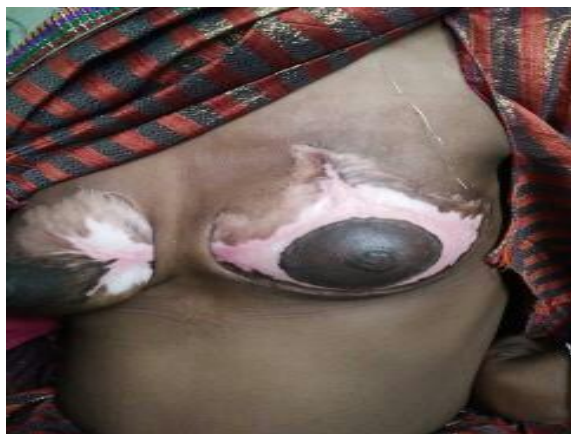

Fig. no. 4: Complete healing within 100 days.

CONCLUSION

A case which was difficult to manage in a tertiary care hospital, was finally cured by Ayurvedic line of treatment, without using modern antibiotics, Silver and iodine compounds and without aid of plastic surgery. Most encouraging finding was that, there was no recurrence even after 7 years.

REFERENCES

1. Amir LH, Forster D, McLachlan H, Lumley J. Incidence of breast abscess in lactating women: report from an Australian cohort. *BJOG*, 2004; 111(12): 1378-81. doi: 10.1111/j.1471-0528.2004.00272.x. PMID: 15663122.
2. Dener C, Inan A. Breast abscesses in lactating women. *World J Surg*, 2003; 27(2): 130-133. [PubMed] [Google Scholar]
3. Kataria K, Srivastava A, Dhar A. Management of lactational mastitis and breast abscesses: review of current knowledge and practice. *Indian J Surg*, 2013; 75(6): 430-5. doi: 10.1007/s12262-012-0776-1. Epub 2012 Dec 12. PMID: 24465097; PMCID: PMC3900741.
4. Breast infection. <https://medlineplus.gov/ency/article/001490.htm#:~:text=Breast%20infections%20are%20usually%20caused,pushes%20on%20the%20milk%20ducts.>
5. K. Rajgopal Shenoy, Anitha Shenoy (Nileshwar). *Differential diagnosis of Leg ulcer and Pressure sore*. Chapter 6 in Manipal Manual of Surgery. CBS Publishers and distributors Pvt. Ltd., New Delhi, 2014; 2: 67-74.
6. Commentary by Late Dr.Garde Ganesh Krishna.'Sarth Vagbhat' Chaukhamba Surbharati Prakashan, Varanasi-221001; Uttarsthan Chapter, 2015; 25 – 15.
7. Commentary by Late Dr.Garde Ganesh Krishna.'Sarth Vagbhat' Chaukhamba Surbharati Prakashan, Varanasi-221001; Uttarsthan Chapter, 2015; 25 – 23.
8. Vaidya Shankar Dattatraya Phansalkar. Chapter 1 Gulwel in Marathi book Ayurvediya Rasayan Chikitsa Part II. Manakarnika Publication, Pune-411 033. First edition, 2011; 46-48.
9. Gupta A, Mahajan S, Sharma R. Evaluation of antimicrobial activity of *Curcuma longa* rhizome extract against *Staphylococcus aureus*. *Biotechnol Rep (Amst)*, 2015; 18, 6: 51-55. doi: 10.1016/j.btre.2015.02.001. PMID: 28626697; PMCID: PMC5466256.
10. Vaidya Shankar Dattatraya Phansalkar. Chapter 4 Triphala in Marathi book Ayurvediya Rasayan Chikitsa Part II. Manakarnika Publication, Pune-411 033. First edition, 2011; 56-59.
11. Vaidya Shankar Dattatraya Phansalkar. Chapter 17 Ashwagandha in Marathi book Ayurvediya Rasayan Chikitsa Part II. Manakarnika Publication, Pune-411 033. First edition, 2011; 17: 96-97.
12. Sarita Gaikwad and Pradip Gaikwad: Effect of Ayurvedic treatment on trophic ulcers of Leprosy- A comparative clinical trial. *Aryavaidyan*, 2010; 23(3): 139- 143.
13. High protein foods for wound healing. <https://www.healthlinkbc.ca/health-topics/high-protein-foods-wound-healing>